PubMed Included

ISSN 0972-9941

Journal of Minimal Access Surgery

JMAS

www.journalofmas.com

Official Publication of
The Indian Association of Gastrointestinal Endo Surgeons

Wolters Kluwer

Medknow

Review Article

Hybrid approach for ventral incisional hernias of the abdominal wall: A systematic review of the literature

Anil Sharma, Chaitanya Sinha, Manish Baijal, Vandana Soni, Rajesh Khullar, Pradeep Chowbey

Department of Minimal Access, Metabolic and Bariatric Surgery, Max Super Speciality Hospital, New Delhi, India

Abstract

With increasing complexity of ventral incisional hernias being operated on, the treatment strategy has also evolved to obtain optimal results. Hybrid ventral hernia repair is a promising technique in management of complex/difficult ventral incisional hernias. The aim of this article is to review the literature and analyse the results of hybrid technique in management of ventral incisional hernia and determine its clinical status and ascertain its role. We reviewed the literature on hybrid technique for incisional ventral hernia repair on PubMed, Medline and Google Scholar database published between 2002 and 2019 and out of 218 articles screened, 10 studies were included in the review. Selection of articles was in accordance with the PRISMA guideline. Variables analysed were seroma, wound infection, chronic pain and recurrence. Qualitative analysis of the variables was carried out. In this systematic review, the incidence of complications associated within this procedure were seroma formation (5.47%), wound infections (6.53%) and chronic pain (4.49%). Recurrence was seen in 3.29% of patients. Hybrid ventral hernia repair represents a natural evolution in advancement of hernia repair. The judicious use of hybrid repair in selected patients combines the safety of open surgery with several advantages of the laparoscopic approach with favourable surgical outcomes in terms of recurrence, seroma and incidence of chronic pain. However, larger multi-centric prospective studies with long term follow up is required to standardise the technique and to establish it as a procedure of choice for this complex disease entity.

Keywords: Complex ventral hernia, enterotomies, hybrid technique, incisional ventral hernia

Address for correspondence: Dr. Chaitanya Sinha, Institute of Minimal Access, Metabolic and Bariatric Surgery, 5th Floor, East Block, Max Super Speciality Hospital, Saket, New Delhi, India.
E-mail: chaitanyasinhamas@gmail.com
Submitted: 19-Jun-2019, **Revised:** 03-Oct-2019, **Accepted:** 20-Jan-2020, **Published:** 12-Sep-2020

INTRODUCTION

There are several laparoscopic techniques for repair of abdominal wall hernias. Laparoscopic intraperitoneal onlay mesh (IPOM) repair was accepted due to the advantages of decreased post-operative morbidity (mainly wound related) compared to the open approach.[1,2] However, some common sequelae associated with laparoscopic IPOM include seroma formation, bulging and failure to restore abdominal wall function.[3,4] In an effort to improve outcomes, laparoscopic IPOM in combination with defect closure (laparoscopic IPOM plus) was suggested for the management of ventral incisional hernias. Several authors have reported improved surgical outcomes.[5]

As more and more complex ventral hernias are being operated on, the treatment strategy has also evolved to obtain the optimal results. Complex incisional hernias

Access this article online	
Quick Response Code:	Website: www.journalofmas.com
	DOI: 10.4103/jmas.JMAS_146_19

How to cite this article: Sharma A, Sinha C, Baijal M, Soni V, Khullar R, Chowbey P. Hybrid approach for ventral incisional hernias of the abdominal wall: A systematic review of the literature. J Min Access Surg 0;0:0.

include hernias with large defects, dense adhesions requiring extensive adhesiolysis, previously implanted mesh and redundant abdominal wall skin and tissue requiring excision. These can be difficult to manage entirely laparoscopically due to increased risk of intraoperative complications, especially enterotomies. Hybrid approach, combining open and laparoscopic techniques, confers the advantages of both techniques. It has been suggested that hybrid approach is a feasible and safe approach for difficult post-operative ventral hernia.[6] It has been shown to reduce patient morbidity due to targeted skin incision and at the same time retaining several advantages of minimal access approach, namely laparoscopic evaluation of the entire abdominal wall with the placement of large intraperitoneal prosthesis.[7] Early conversion to the combined technique is associated with less technical difficulty, decreased operative time, lower enterotomy rates, shorter hospital stay and improved patient outcomes.[8]

The objective of this study was to review and analyse the available literature on the hybrid technique of ventral incisional hernia repair and determine the clinical status and surgical outcomes of this technique in the management of complex ventral incisional hernia.

MATERIALS AND METHODS

In this article, two independent authors reviewed the literature on the hybrid IPOM technique for the management of ventral incisional hernia repair. PubMed, Medline and Google Scholar electronic database search was performed using the following keywords, (ventral hernia OR incisional hernia AND hybrid technique AND repair AND surgery). Articles with a follow-up period of < 12 months were excluded from the study. Out of 964 articles identified through our database search, the abstracts of 218 publications were screened. Published between 2002 and 2019, for the present analysis, 10 publications were found to be of interest. A cross-reference search was also carried out from these articles, and relevant manuscripts were included in the study. Out of these, 9 were original articles.[6-14] One article was a randomised controlled trial (RCT) study comparing laparoscopic and hybrid techniques of incisional hernia repair. Hybrid technique data were extracted and included in the study.[15] Another study had included primary, recurrent and incisional ventral hernia in their article, and only incisional hernia data were extracted for the inclusion in this study.[14]

Three articles were not in the English language and were excluded. One article using a biological mesh for hybrid repair was also excluded. Studies on hybrid technique repair of parastomal hernia were also excluded.

According to the PRISMA guidelines,[16] a systematic presentation, and synthesis, of the characteristics and findings of the included studies has been made [Figure 1]. Patients' demographic, intra-operative and post-operative data were collected and analysed. Patient demographics included were age, gender, body mass index (BMI) and co-morbidities, including smoking was recorded [Table 1]. Intra-operative data included defect size and operative time [Table 2]. The post-operative variables studied were seroma formation, wound infections, chronic pain and recurrence rates [Table 2]. Two-hundred and thirty-two patients were analysed from 10 studies, and their results are summarised in Tables 1-3.

Surgical technique of hybrid intraperitoneal onlay mesh

The reviewed literature describes two techniques of hybrid repair. In the first method of hybrid repair as described in the articles reviewed,[6,7,9,15] initial laparoscopy was converted to open adhesiolysis and repair with or without sac excision, followed by laparoscopic IPOM placement. In the second method of hybrid repair as described in the reviewed articles,[8,10-13] involves exposure of the defect through an incision over previous scar, adhesiolysis performed with or without sac excision and defect closed, followed by laparoscopic IPOM placement to complete the repair.

All the studies have used synthetic mesh for hernia repair, with a minimum overlap of 3 cm (3–7 cm) on all sides. The fixation of the mesh was accomplished by a combination of tackers and transfascial sutures.

Outcomes of hybrid intraperitoneal onlay mesh

Altogether, 232 patients with incisional ventral hernias were included from the ten articles reviewed. Variables analysed were seroma formation, wound infection, chronic pain and recurrence rates [Table 2].

Seroma

In this review, the pooled seroma rate was 5.47% (0%–14.3%). All the seroma reported in the studies were managed conservatively and resolved spontaneously, without the need for any intervention. One study in a prospective RCT found significantly less seroma formation at 1 month in the hybrid group compared to laparoscopic IPOM (45.3% vs. 67%, $P = 0.004$). However, this outcome had no impact on recurrence rates at 1-year of follow-up.[15]

Seroma formation is the most common complication after laparoscopic IPOM, which apart from giving a poor aesthetic outcome, also causes discomfort, pain and presents a risk of infection.[17] In open onlay repair with

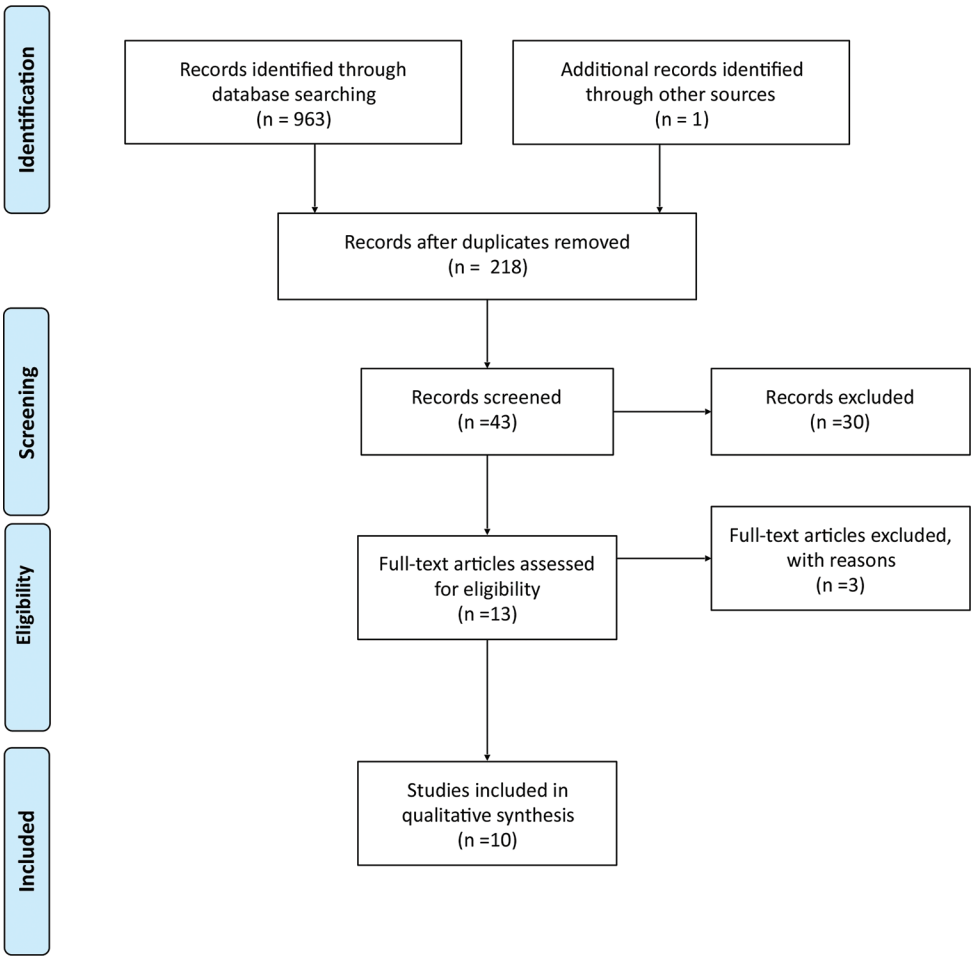

Figure 1: PRISMA flowchart of study selection

Table 1: Characteristics of studies included in this study with patient demographics

Author	Year	Study type	Patients number	Age (year)	Gender (F/M)	BMI (mean)	Co-morbidity	Smoker/ tobacco use	Follow up (months)
Eitan A *et al*.[6]	2002	Retrospective	7	45-63	6/1	N/R	N/R	N/R	36.4 (16-53)
Sharma A[7]	2007	Retrospective	26	N/R	18/8	N/R	N/R	N/R	51 (8 to 112)
Griniatsos J *et al*.[8]	2009	Retrospective	6	76 (mean)	2/4	26.6-33.4	N/R	N/R	12 (maximum)
Yun Ji *et al*.[9]	2013	Retrospective	16	59.6+/-10.2	N/R	32.4 +/- 4.7	HTN-9 DM-5 COPD-3	8 (38%)	14.9 +/-10.3
Stoikes N *et al*.[10]	2013	Retrospective	7	65 (34-80)	N/R	38 (28-62)	HTN-4 CAD-3 DM-1	N/R	15 (3-63)
Ozturk G *et al*.[11]	2015	Retrospective	16	59 (39-74)	15/1	29.9 (25-38)	N/R	N/R	12
Romanowska M *et al*.[12]	2015	Retrospective	15	65.7 (39-81)	9/6	26.1 (22-31.2)	HTN-11 DM-7 CAD-6 COPD-2 CKD-4	N/R	32 (maximum)
Meytes V *et al*.[13]	2017	Retrospective	19	46 (33-79)	12/7	34.7 (28.8-45.4)	HTN-8 DM-8 CAD-1	8 (42%)	12
Siirtola MA *et al*.[15]	2018	Prospective RCT	90	60 +/- 12.8	55/35	29.2 +/- 4.2	N/R	11 (12.2%)	12
Wasim MD *et al*.[14]	2019	Retrospective	30	45 (25-60)	55/20	26 (20-35)	N/R	N/R	24

N/R: Not reported, HTN: Hypertension, DM: diabetes, CAD: Coronary artery disease, CKD: Chronic kidney disease, COPD: Chronic obstructive pulmonary disease

defect closure for incisional hernia, seroma formation has been reported in the range between 38.5 and 45.6%.[18] In standard laparoscopic IPOM (sIPOM), the incidence of clinical seroma has been reported from 0.5% to 78%.[19,20]

Table 2: Complications in different studies

Author	Operating time (min)	Hospital stay (days)	Defect size	Seroma (%)	Wound infection (%)	Chronic pain	Recurrence
Eitan A *et al*.[6]	N/R	N/R	N/R	0	0	0	0
Sharma A[7]	124	2.1	N/R	3 (11.5%)	1 (3.8%)	4 (15.3%)	1 (3.8%)
Griniatsos J *et al*.[8]	128-207	3-7	116-187 cm sq	0	0	0	0
Yun Ji *et al*.[9]	110.7 +/- 34.7	4.7 +/- 1.9	190.5 +/- 84.5 cm sq	N/R	0	N/R	0
Stoikes N *et al*.[10]	318 (210-405)	5 (4-7)	10.6 x 8.3 cm (mean)	1 (14.3%)	2 (28.6%)	N/R	0
Ozturk G *et al*.[11]	77.3 (50-120)	2.8 (2-8)	12.8 cm (10-19.5 cm)	0	3 (18.75%)	N/R	1 (6.25%)
Romanowska M *et al*.[12]	100-180	N/R	N/R	N/R	2 (13.3%)	N/R	0
Meytes V *et al*.[13]	153 (69-281)	1.1 (1-3)	2.5-15 cm sq (5.94 cm sq mean)	0	1 (5%)	0	1 (5%)
Sirtola MA *et al*.[15]	N/R	N/R	10.5 cm +/- 8.9 cm	5 (6%)	N/R	4 (5%)	5 (6%)
Wasim MD *et al*.[14]	N/R	2-3	6.16 cm (5-8 cm)	2 (2.7%)	1 (1.3%)	0	0

Table 3: Percentage distribution of complications

Complications	No of patients	Percentage
Seroma	11/201	5.47% (0-14.3%)
Wound infection	10/153	6.53% (0-28.6)
Chronic pain	08/178	4.49% (0-15.3)
Recurrence	08/243	3.29% (0-6.3%)

In a multi-centre, registry-based, propensity score-matched comparison of 9907 patients comparing laparoscopic IPOM to open sublay technique for elective incisional hernia repair, a statistically significant difference was reported in seroma rates between the two groups (lap IPOM 1.94% vs. open sublay 5.12%; $P < 0.001$).[21]

In a review of literature of IPOM-Plus, it has been reported that the closure of fascial defect reduces the incidence of seroma in patients (0%–11.43%).[5] In another study, a meta-analysis of closure of the fascial defect during laparoscopic incisional and ventral hernia repair, closure of fascial defect demonstrated the lower rate of seroma as compared to non-closure of defect (2·5% vs. 12·2%, $P < 0.001$).[22] IEHS guidelines have given a low-level recommendation (Grade D: No recommendation at all) to include hernia sac during fascial closure to prevent seroma formation.[23]

Wound infection

The pooled wound infection rate in our study was 6.53% (0%–28.6%). One of the studies in the articles reviewed reported infection in two patients (28.6%), resulting in re-operations and mesh excision. One patient had a BMI of 62 with two prior periumbilical incisional hernias repair, and the other patients had undergone prior ventral hernia repairs with a recurrent large incisional hernia.[10] Ozturk *et al*.[11] reported wound infection in 18.75% patients; however, all of them were managed conservatively without necessitating mesh extraction in any of the patients.

In a systematic review and meta-analysis on open ventral hernia repair, ten studies reported surgical site infection in their results, and the pooled rates were 16.9% (0%–33%) for onlay, 31.3% (8.7%–37.1%) for inlay and 3.7% (0%–21%) for sublay placement of mesh.[24]

In a multi-centre registry-based study of laparoscopic IPOM,[21] deep wound infection rates reported were laparoscopic IPOM 0.30% vs. open sublay 1.34%; $P < 0.001$. In another study, the wound infection rate of 0.64% and mesh infection rate of 0.16% have been reported after laparoscopic ventral/incisional hernia repair.[25]

Chronic pain

The pooled chronic pain rate in our study was 4.49% (0%–15.3%). Chronic pain after laparoscopic repair of abdominal wall hernias is an under-reported outcome of the procedure. Six studies have analysed chronic pain as surgical complication after hybrid IPOM in 4.49% of patients.[6-8,13-15] The rest of the four articles did not report chronic pain as the outcome in their study.

Sharma *et al*.[7] reported chronic pain in 15.3% of their patients. In a prospective, randomised, multicentre study by Ahonen-Siirtola *et al*.,[15] chronic pain was seen in 5% of patients. However, none of the authors have defined the criteria for diagnosing chronic pain.

Mesh fixation with transfascial sutures may cause ischaemic injuries to abdominal wall musculature or neuromuscular entrapment, resulting in post-operative chronic pain. Tackers used for fixation may also cause nerve entrapment.[26,27] In a retrospective study of laparoscopic ventral/incisional hernia repair in 1242 patients, chronic pain occurred in 14.7% patients, with the highest incidence found in the group of patients where a combination of tackers and transfascial sutures were used for mesh fixation (16.4%); however, the association was not statistically significant ($P = 0.078$).[25] All the articles included in our study have used a combination of tackers and transfascial sutures for mesh fixation.

Bedi *et al*.[28] in a review of literature, including 34 original articles on laparoscopic ventral and incisional hernia repair

reported chronic pain as complication in 2.75% of patients. In a meta-analysis of closure of the fascial defect during laparoscopic incisional and ventral hernia repair, when compared to non-closure of defect, no significant difference in pain scores was observed (mean 2 · 47 vs. 3 · 68). However, the definition and method of recording pain were different between different studies, making the comparison difficult.[22]

Recurrence

The pooled recurrence rate in our study was 3.29% (0%–6.3%). One of the most important surgical outcome measures after any hernia repair is the recurrence rate. In our analysis, eight patients had recurrences. Sharma *et al*.[7] had one recurrence in their study, with a mean follow-up period of 51 months. Eitan and Bickel *et al*.[6] had no recurrences in their study, with a mean follow-up period of 36.4 months. Most studies reported no recurrences.

In open onlay technique in incisional hernia repair, recurrence rates reported ranges from 0 to 32%, with a mean value of 9.9%, and a comparison to literature data on the sublay operation showed more post-operative complications, in particular wound complications and seroma, with onlay technique. However, comparable recurrence rates were identified.[18]

Another review of literature and meta-analysis for open ventral hernia repair has reported variable recurrence rates depending on the location of the mesh, the pooled recurrence rates being 16.5% (0%–36%) for onlay, 30.2% (0%–80%) for inlay, 7% (0%–48%) for sublay and 14.7% (0%–56%) for underlay.[24] In open IPOM with a bridging situation, the recurrence rates have been reported in the range between 0% and 61%, with a mean value of 12.6%.[29]

In a single-centre study of 1242 patients of laparoscopic ventral/incisional hernia repair with a mean follow-up of 11.6 months, the recurrence rate was reported to be 4.4%. There was also a significant correlation between the use of staplers alone and recurrences.[25] In a review of literature of closure versus non-closure of fascial defects in laparoscopic ventral incisional hernias, the overall recurrence rate of IPOM-Plus was 0%–7.7%, with a median follow-up period of 10.5–50.4 months.[5]

DISCUSSION

Since the introduction of the laparoscopic approach by LeBlanc and Booth in 1993, minimal access technique has gained widespread popularity, primarily because of its advantages of less morbidity, short hospital stay, early return to activities and ability to identify additional or occult defects in the abdominal wall.[30] Despite the advantages of laparoscopic approach, post-operative morbidity has been reported in 3%–18% of cases.[31,32] With growing experience, it was realised that purely laparoscopic procedures were associated with higher failure rates in cases of complex abdominal hernias. Rather than matching the patient to a certain surgical technique, the technique should be tailored to the patients characteristic and the defect size. The recurrence rates in laparoscopic IPOM, contrary to expectations, still range between 4.4% and 29%, almost at par with the open technique.[25,33,34] This was partly due to the widespread application of the laparoscopic IPOM technique to all ventral hernias, irrespective of its complexity and the understanding of the disease process. In our review, recurrence rates after the hybrid technique of incisional hernia repair ranged from 0 to 6.3%, which is less than what most literature has reported for open techniques of repair and comparable to laparoscopic IPOM and IPOM plus for the repair of ventral incisional hernias.[5,29]

Seroma formation is a common complication after ventral hernia repair. In open onlay repair, the seroma rate has been reported to range between 38.5% and 45.6%.[18] Seroma rates for standard IPOM have been reported to range from 0.5% to 78%. In IPOM plus, seroma rates have been reported to range from 0% to 11.43%. Seroma formation in our review ranged from 0% to 14.3%, with a mean of 5.47%, which is lower than open onlay repair and standard IPOM technique and comparable to IPOM plus. However, only two studies in the articles reviewed have mentioned the excision of sac as part of the surgical technique.[14,15]

Wound infection rates have been reported to be 16.9% for open onlay repair, 31.3% for open inlay repair and 3.7% for open sublay repair.[24] Wound infection rates in standard IPOM have been reported to range from 0.30% to 0.60%.[21,25] In our review, the wound infection rate was 6.53%, which is less than what literature has reported for open onlay and open inlay repair and comparable to open sublay repair. However, wound infection rates were lower for standard IPOM technique.

Chronic pain after standard IPOM has been reported in the range of 2.75%–14.7%;[25,28] however, both the articles have included both primary and incisional ventral hernias in their study. In this review, the incidence of chronic pain was 4.49%. It should be noted that the criteria for diagnosing chronic pain have not been well described in our included studies.

Longer follow-up is essential to assess the true rate of recurrence, and at least a 3-year follow-up has been suggested to know the incidence of delayed recurrences.[35] Most of the studies included in this review have reported

a maximum follow-up period of 12 months, with only two studies having a mean follow-up period of more than 3 years. This highlights the need to have more studies with longer follow-up periods to know the recurrence rates after the hybrid IPOM technique. Another limitation in our review is the variation in defect size across different studies, with one study reporting an average defect size 5.94 cm^2,[13] which could have an impact on surgical outcomes.

CONCLUSION

In conclusion, this systematic review of the literature suggests that hybrid ventral hernia repair is a promising technique in the management of complex/difficult ventral incisional hernias and represents a natural evolution in advancement of hernia repair. The judicious use of hybrid repair in selected patients combines the safety of open surgery with several advantages of the laparoscopic approach with favourable surgical outcomes in terms of recurrence, seroma and incidence of chronic pain. It reduces the morbidity of large abdominal flaps of open repair while preserving the benefits of laparoscopic approach such as the placement of a large underlay mesh and fixation under vision and identification of occult hernias. It allows safe adhesiolysis and safe bowel handling and reduction in patients of incarcerated hernia with extensive adhesions, reducing the risks of inadvertent enterotomies. However, larger multi-centric prospective studies with longer follow-up periods are required to standardise the technique and to establish it as the procedure of choice for this complex disease entity.

Financial support and sponsorship

Nil.

Conflicts of interest

There are no conflicts of interest.

REFERENCES

1. Olmi S, Scaini A, Cesana GC, Erba L, Croce E. Laparoscopic versus open incisional hernia repair: An open randomized controlled study. Surg Endosc 2007;21:555-9.
2. Zhang Y, Zhou H, Chai Y, Cao C, Jin K, Hu Z. Laparoscopic versus open incisional and ventral hernia repair: A systematic review and meta-analysis. World J Surg 2014;38:2233-40.
3. Schoenmaeckers EJ, Wassenaar EB, Raymakers JT, Rakic S. Bulging of the mesh after laparoscopic repair of ventral and incisional hernias. JSLS 2010;14:541-6.
4. Kurmann A, Visth E, Candinas D, Beldi G. Long-term follow-up of open and laparoscopic repair of large incisional hernias. World J Surg 2011;35:297-301.
5. Suwa K, Okamoto T, Yanaga K. Closure versus non-closure of fascial defects in laparoscopic ventral and incisional hernia repairs: A review of the literature. Surg Today 2016;46:764-73.
6. Eitan A, Bickel A. Laparoscopically assisted approach for postoperative ventral hernia repair. J Laparoendosc Adv Surg Tech A 2002;12:309-11.
7. Sharma A, Mehrotra M, Khullar R, Soni V, Baijal M, Chowbey PK. Limited-conversion technique: A safe and viable alternative to conversion in laparoscopic ventral/incisional hernia repair. Hernia 2008;12:367-71.
8. Ji Y, Zhan X, Wang Y, Zhu J. Combined laparoscopic and open technique for the repair of large complicated incisional hernias. Surg Endosc 2013;27:1778-83.
9. Griniatsos J, Yiannakopoulou E, Tsechpenakis A, Tsigris C, Diamantis T. A hybrid technique for recurrent incisional hernia repair. Surg Laparosc Endosc Percutan Tech 2009;19:e177-80.
10. Stoikes N, Quasebarth M, Brunt LM. Hybrid ventral hernia repair: Technique and results. Hernia 2013;17:627-32.
11. Ozturk G, Malya FU, Ersavas C, Ozdenkaya Y, Bektasoglu H, Cipe G, *et al*. A novel reconstruction method for giant incisional hernia: Hybrid laparoscopic technique. J Minim Access Surg 2015;11:267-70.
12. Romanowska M, Okniński T, Pawlak J. Hybrid technique for postoperative ventral hernias-own experience. Wideochir Inne Tech Maloinwazyjne 2016;10:534-40.
13. Meytes V, Lee A, Rivelis Y, Ferzli G, Timoney M. Hybrid fascial closure with laparoscopic mesh placement for ventral hernias: A single surgeon experience. Ann Laparosc Endosc Surg 2017;2:55-55.
14. Wasim MD, Muddebihal UM, Rao UV. Hybrid: Evolving Techniques in Laparoscopic Ventral Hernia Mesh Repair. J Min Access Surg 0;0:0.
15. Ahonen-Siirtola M, Nevala T, Vironen J, Kössi J, Pinta T, Niemeläinen S, *et al*. Laparoscopic versus hybrid approach for treatment of incisional ventral hernia: A prospective randomised multicentre study, 1-year results. Surg Endosc 2020;34:88-95.
16. Moher D, Liberati A, Tetzlaff J, Altman DG; PRISMA Group. Preferred reporting items for systematic reviews and meta-analyses: The PRISMA statement. BMJ 2009;339:b2535.
17. Edwards C, Angstadt J, Whipple O, Grau R. Laparoscopic ventral hernia repair: Postoperative antibiotics decrease incidence of seroma-related cellulitis. Am Surg 2005;71:931-5.
18. Weitzman PD, Danson MJ. Citrate synthase. Curr Top Cell Regul 1976;10:161-204.
19. Parker HH 3rd, Nottingham JM, Bynoe RP, Yost MJ. Laparoscopic repair of large incisional hernias. Am Surg 2002;68:530-3.
20. Birch DW. Characterizing laparoscopic incisional hernia repair. Can J Surg 2007;50:195-201.
21. Köckerling F, Simon T, Adolf D, Köckerling D, Mayer F, Reinpold W, *et al*. Laparoscopic IPOM versus open sublay technique for elective incisional hernia repair: A registry-based, propensity score-matched comparison of 9907 patients. Surg Endosc 2019;33:3361-9.
22. Tandon A, Pathak S, Lyons NJ, Nunes QM, Daniels IR, Smart NJ. Meta-analysis of closure of the fascial defect during laparoscopic incisional and ventral hernia repair. Br J Surg 2016;103:1598-607.
23. Bittner R, Bingener-Casey J, Dietz U, Fabian M, Ferzli GS, Fortelny RH, *et al*. Guidelines for laparoscopic treatment of ventral and incisional abdominal wall hernias (International Endohernia Society (IEHS)-part 1. Surg Endosc 2014;28:2-9.
24. Holihan JL, Nguyen DH, Nguyen MT, Mo J, Kao LS, Liang MK. Mesh location in open ventral hernia repair: A systematic review and network meta-analysis. World J Surg 2016;40:89-99.
25. Sharma A, Mehrotra M, Khullar R, Soni V, Baijal M, Chowbey PK. Laparoscopic ventral/incisional hernia repair: A single centre experience of 1,242 patients over a period of 13 years. Hernia 2011;15:131-9.
26. Franklin ME Jr., Gonzalez JJ Jr., Glass JL, Manjarrez A. Laparoscopic ventral and incisional hernia repair: An 11-year experience. Hernia 2004;8:23-7.
27. Lau H, Patil NG, Yuen WK, Lee F. Laparoscopic incisional hernioplasty utilising on-lay expanded polytetrafluoroethylene DualMesh: Prospective study. Hong Kong Med J 2002;8:413-7.
28. Bedi AP, Bhatti T, Amin A, Zuberi J. Laparoscopic incisional and ventral hernia repair. J Minim Access Surg 2007;3:83-90.

29. Köckerling F, Lammers B. Open intraperitoneal onlay mesh (IPOM) technique for incisional hernia repair. Front Surg 2018;5:66.
30. LeBlanc KA, Booth WV. Laparoscopic repair of incisional abdominal hernias using expanded polytetrafluoroethylene: Preliminary findings. Surg Laparosc Endosc 1993;3:39-41.
31. Chowbey PK, Sharma A, Khullar R, Mann V, Baijal M, Vashistha A. Laparoscopic ventral hernia repair. J Laparoendosc Adv Surg Tech A 2000;10:79-84.
32. Heniford BT, Park A, Ramshaw BJ, Voeller G. Laparoscopic ventral and incisional hernia repair in 407 patients. J Am Coll Surg 2000;190:645-50.
33. Carbajo MA, Martp del Olmo JC, Blanco JI, Toledano M, de la Cuesta C, Ferreras C, *et al*. Laparoscopic approach to incisional hernia. Surg Endosc 2003;17:118-22.
34. Sauerland S, Walgenbach M, Habermalz B, Seiler CM, Miserez M. Laparoscopic versus open surgical techniques for ventral or incisional hernia repair. Cochrane Database of Systematic Reviews 2011;(3):CD007781.
35. LeBlanc KA, Booth WV, Whitaker JM, Bellanger DE. Laparoscopic incisional and ventral herniorrhaphy in 100 patients. Am J Surg 2000;180:193-7.